

---

## Clinical Quiz

---

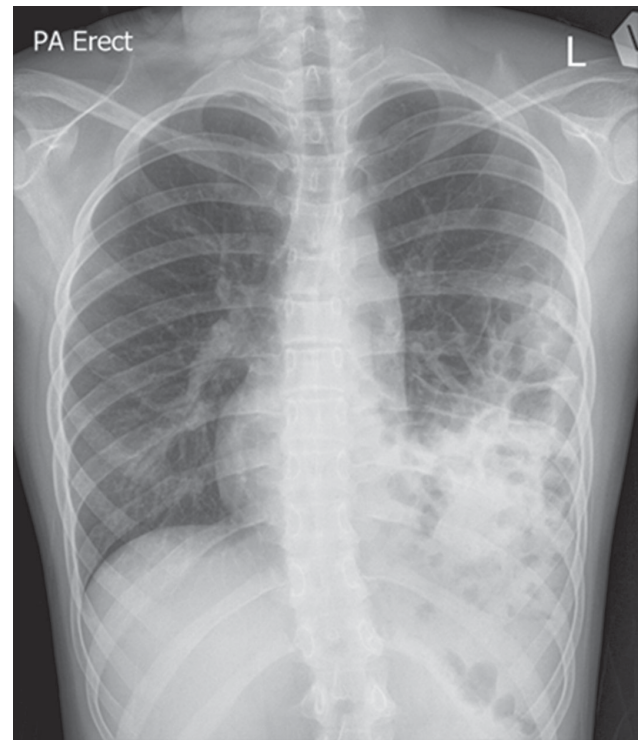
### What is the Diagnosis?

SSK *Ho*, TCW *Wong*

---

This 12-year-old girl presented with one-week history of running nose, sore throat and dry cough that did not improve with symptomatic treatment. She was afebrile and there was no systemic upset. Over the past few years, she has experienced multiple episodes of "bronchitis" and abdominal pain that were treated with antibiotics and antispasmodics intermittently. Antenatal and postnatal history were unremarkable. There was no history of trauma or surgery.

On examination, she was afebrile without respiratory distress. Her throat was mildly congested. There was reduced breath sounds on the left side of the chest and 'coarse crackles' at the left axilla. Blood results including complete blood picture, C-reactive protein and erythrocyte sedimentation rate were all normal. A postero-anterior chest radiograph was taken (Figure 1).



**Figure 1**

---

The clinical quiz was prepared by:

SSK **Ho**

TCW **Wong**

Bachelor of Medicine and Bachelor of Surgery Undergraduate Year 5, Faculty of Medicine, The Chinese University of Hong Kong, Hong Kong

Answer to "Clinical Quiz" on Pages 317-318

N.B. The Editors invite contributions of illustrative clinical cases or materials to this section of the journal.