

Clinical Quiz

What is the Diagnosis?

GTK **MOK**, JPW **CHIANG**, JCC **YEUNG**, BHY **CHUNG**

Our patient was born to non-consanguineous Chinese parents at 39 weeks gestation with a birth weight of 2.32 kg. The mother, a chronic smoker, suffered from depression and anxiety disorder requiring anti-depressant and anxiolytic treatment. The family history was

unremarkable. Figure 1 shows the eye findings of our patient. She also had cleft palate. Examination of the other systems was unremarkable. Her development and growth was normal at 6 months of age.

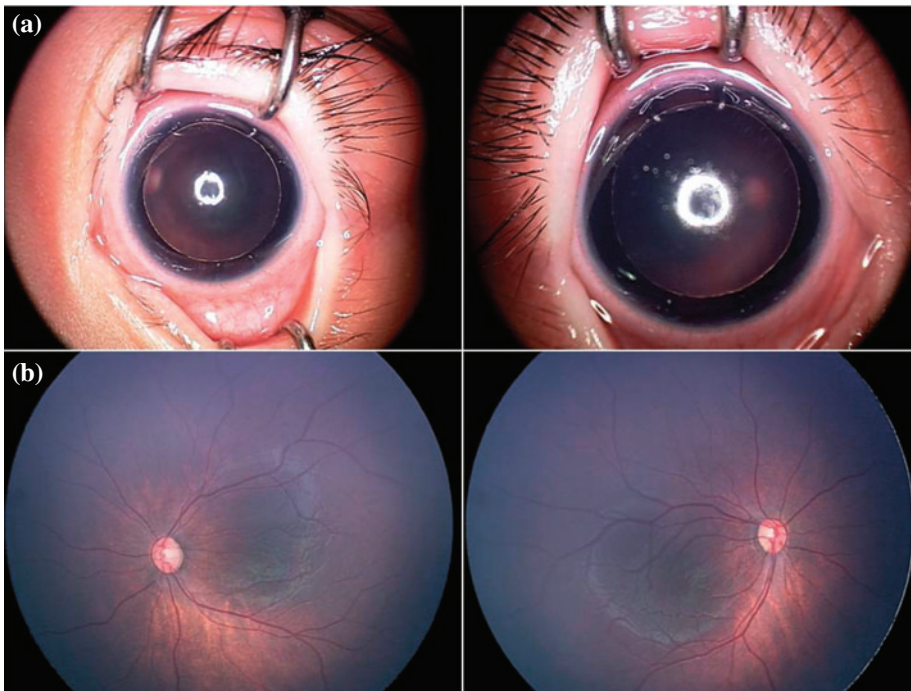


Figure 1 Clinical photograph of our proband from examination under anaesthesia: (a) anterior segment and (b) fundus.

The clinical quiz was prepared by:

GTK **MOK**
BHY **CHUNG**
Department of Paediatrics & Adolescent Medicine, The University of Hong Kong, Queen Mary Hospital, Pokfulam, Hong Kong

JPW **CHIANG**
Casey Eye Institute Molecular Diagnostic Laboratory, Portland, Oregon, USA

JCC **YEUNG**
Premier Medical Centre, Hong Kong

Answer to "Clinical Quiz" on Pages 216-219

N.B. The Editors invite contributions of illustrative clinical cases or materials to this section of the journal.