

Clinical Quiz

What is the Diagnosis?

WY LEUNG, APY LIU, BHY CHUNG

A baby boy was born prematurely at 30 weeks with birth weight of 1.48 kg by normal spontaneous delivery. Both parents were ethnic Chinese and no antenatal care was performed for the pregnancy. Family history was otherwise insignificant. Early neonatal course was remarkable for mild respiratory distress syndrome, clinical sepsis and neonatal jaundice.

On Day 23, painful swelling was noted over the left thigh during routine nursing care. Examination showed white sclera. A skeletal survey was performed (Figures 1-4).

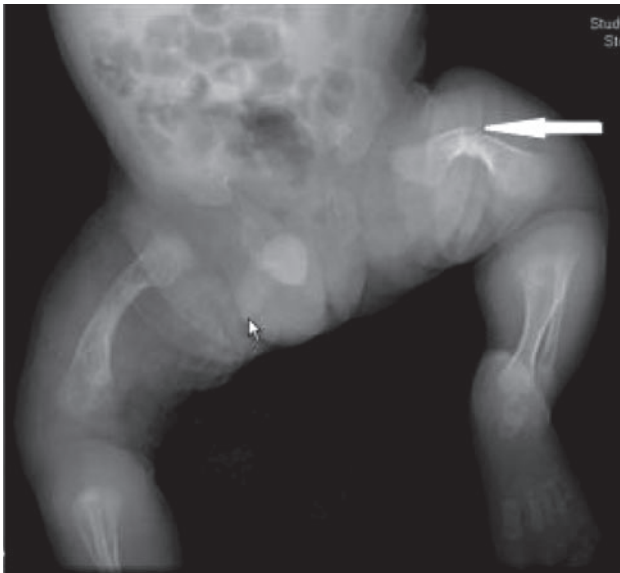

Figure 1 Lower limbs.

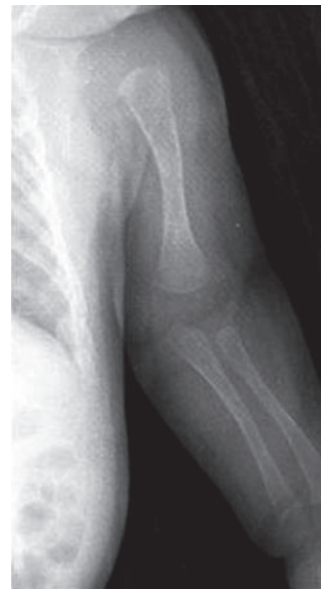

Figure 2 Left upper limb.

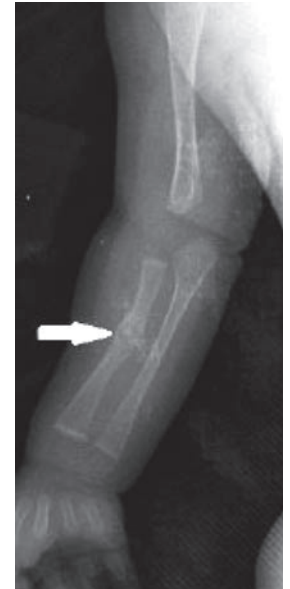

Figure 3 Right upper limb.

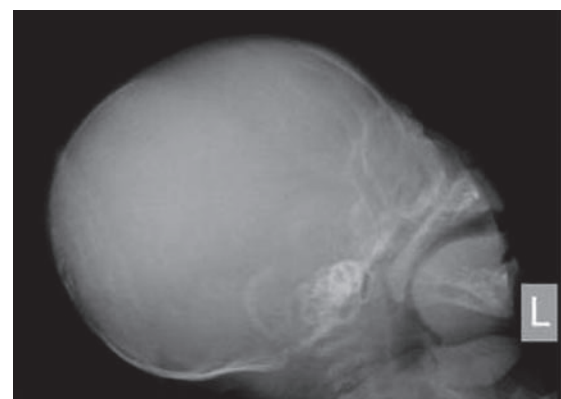


Figure 4 Skull.

The clinical quiz was prepared by:

WY LEUNG
MBBS II Student, Elective Module in Clinical Genetic Program
Department of Paediatrics & Adolescent Medicine, The University
of Hong Kong, Queen Mary Hospital, Pokfulam, Hong Kong

APY LIU
BHY CHUNG
Department of Paediatrics & Adolescent Medicine, The University
of Hong Kong, Queen Mary Hospital, Pokfulam, Hong Kong

Answer to "Clinical Quiz" on Pages 192-194

N.B. The Editors invite contributions of illustrative clinical cases or materials to this section of the journal.