

Clinical Quiz

What is the Diagnosis?

APY LIU, BHY CHUNG, TC YUNG

A 7-year-old boy was admitted to the Paediatric ward after an episode of syncope. According to school teacher, the patient collapsed and developed symmetrical limb twitching lasting for 30 seconds during a basketball game. The child regained consciousness shortly afterwards, there was no history of palpitation, chest discomfort or dyspnoea. He enjoyed good past health

except for one other episode of syncope which occurred at the age of 5 while the patient was running, blood tests and a cranial computed tomography was normal. Family history was negative for unexplained syncope, seizure, arrhythmia or sudden death. A thorough physical examination was unrevealing. An electrocardiogram (ECG) was performed (Figure 1).

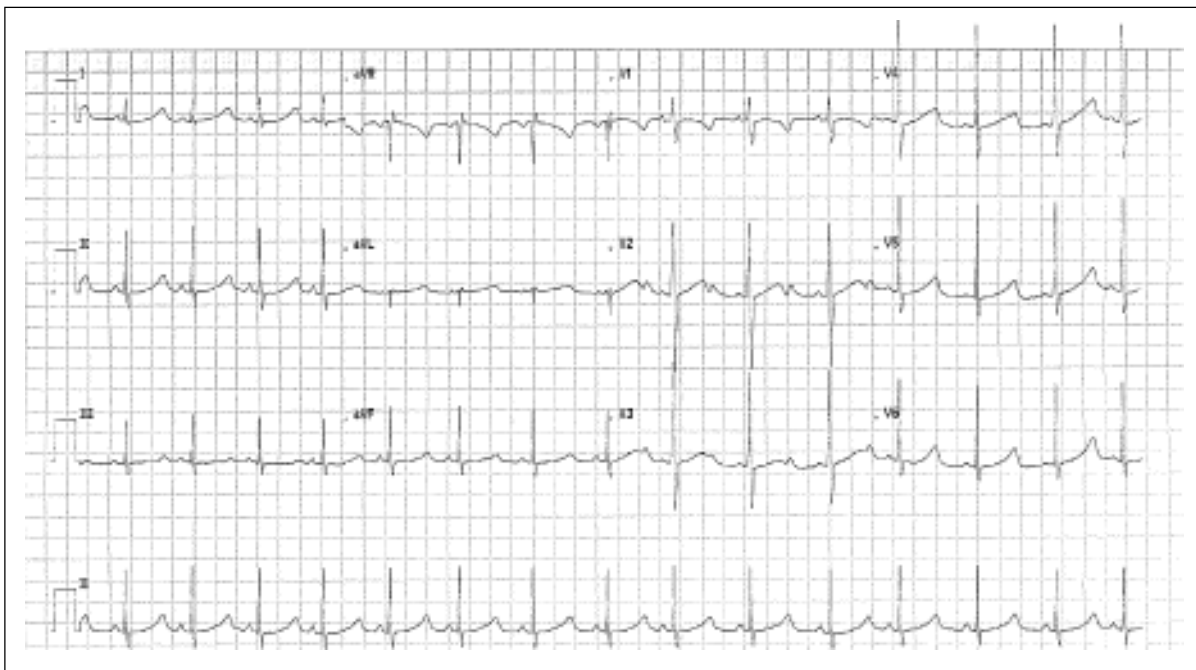


Figure 1.

The clinical quiz was prepared by:

APY LIU

BHY CHUNG

Department of Paediatrics & Adolescent Medicine, The University of Hong Kong, Queen Mary Hospital, Pokfulam, Hong Kong

TC YUNG

Division of Paediatric Cardiology, Department of Paediatrics and Adolescent Medicine, The University of Hong Kong, Queen Mary Hospital, Pokfulam, Hong Kong

Answer to "Clinical Quiz" on Pages 137-138

N.B. The Editors invite contributions of illustrative clinical cases or materials to this section of the journal.