

A Fatal Case of Brainstem Encephalitis Caused by Human Parechovirus

MM YAU, Q MOK, P PRABHAKAR

Abstract

There is increasing recognition of human parechovirus (HPeV) as a neurotropic virus, especially type 3, which can cause sepsis and encephalitis in young infants. We present a case of neonatal brainstem encephalitis caused by HPeV and review the fifteen published cases in the literature. This is the first report of HPeV causing brainstem encephalitis. Earlier use of polymerase chain reaction testing for HPeV should be considered in appropriate cases.

Key words

Brainstem encephalitis; Human parechovirus; Neonate

Introduction

Human parechovirus (HPeV) is a single-stranded non-enveloped RNA virus belonging to the picornaviridae family. HPeV 1 and 2, previously named echovirus 22 and 23, were discovered in 1961. HPeV type 3 was first reported in Japan in 2004, when it was isolated in the stools of an infant with transient paralysis.¹ Subsequently more types of HPeV have been identified. To our knowledge, this is the first case of neonatal brainstem encephalitis caused by HPeV in the literature.

Department of Paediatric and Adolescent Medicine, Tseung Kwan O Hospital, 2 Po Ning Lane, Hang Hau, Tseung Kwan O, N.T., Hong Kong, China; Department of Neurology, Great Ormond Street Hospital NHS Trust, London, United Kingdom

MM YAU (邱文謙) MBBS, MRCPCH

Great Ormond Street Hospital NHS Trust, London, United Kingdom

Q MOK FRCP, FRCPI

P PRABHAKAR MBBS, FRCPCH

Correspondence to: Dr MM YAU

Received November 8, 2010

Case Study

A female baby was born in good condition weighing 2.64 kg to non-consanguineous Somali parents. An emergency Caesarean section was performed for maternal pyrexia at 36 weeks gestation. Maternal high vaginal swab was positive for group B Streptococcus, and the baby was treated for one week with parenteral antibiotics. There was no significant family history of neurological or metabolic diseases. She subsequently presented at three weeks of age with a 24 hour history of poor feeding, irritability, seizures and apnoea. On admission, she was hypothermic (32 degrees Celsius) and hypotensive. She received fluid resuscitation and was intubated, ventilated, and transferred to Neonatal Intensive Care Unit (NICU), Great Ormond Street Hospital for Children, London.

She was treated for presumed neonatal sepsis with parenteral antimicrobials and acyclovir, as well as inotropes for cardiovascular instability. She was commenced on maintenance phenobarbitone for seizures, with levels within therapeutic range. The initial workup for infective aetiology did not identify a specific cause. Lumbar puncture was a slight traumatic tap. Cerebrospinal fluid (CSF) examination showed total white cell count of $25 \times 10^6/L$, with 100% lymphocytes, and red cell count of $250 \times 10^6/L$, CSF protein was raised at 1.7 g/dL. CSF and serum glucose were normal.

It was negative for cytomegalovirus DNA, enterovirus RNA, herpes simplex virus DNA by PCR. Bacterial cultures from CSF, blood, throat swab and stool were negative. Nasopharyngeal aspirate polymerase chain reaction (PCR) for rhinovirus 1 and 2, parainfluenza 1, 2 and 3, influenza A/B, Respiratory Syncytial Virus, human metapneumovirus, adenovirus and enterovirus were negative. Blood for Epstein-Barr virus viral capsid antigen immunoglobulin G was negative. Extensive metabolic screening was negative.

Sedatives were weaned off following cardiovascular stabilisation but she had very little spontaneous movement, no respiratory effort and bilateral pinpoint pupils. There was no improvement after a trial of naloxone. Electroencephalogram (EEG) at that time showed generally low amplitude but no evidence of encephalopathy or epileptic discharges. Magnetic resonance imaging (MRI) of the brain on day 3 of admission showed marked signal abnormality in white matter and swelling in the brainstem and upper cervical cord, with restricted diffusion, compatible with encephalitis (Figure 1). Somatosensory evoked potentials (SSEPs) performed on day 7 of admission obtained a response from cervical cord but no cortical response, indicating a severe disorder of brainstem function.

Blinking, corneal and gag reflexes were absent. Deep tendon reflexes were present. Repeated EEG showed frequent epileptiform discharges, and phenobarbitone was continued. Nerve conduction study and electromyography (EMG) showed normal conduction in legs, but motor and sensory studies were affected in the arms and her tongue was denervated. A second MRI brain scan on day 11 of admission showed resolving oedema with gliotic changes in the brainstem (Figure 1). A course of pulsed methylprednisolone and intravenous immunoglobulin did not result in any improvement. Further virological investigations were carried out, including a test for HPeV PCR in CSF, which was positive. The parechovirus RNA assay was developed in-house at Micropathology Ltd. Its target is the 5' UTR gene of HPeV type 1 to 6. It is a nested RT-PCR assay and the second round is performed on a realtime PCR device (Roche LightCycler) using Sybr Green and melting curve analysis as the detection method.

Her neurological state remained unchanged with absent brainstem reflexes and ventilator dependency. A third MRI brain scan on day 23 of admission showed a gliotic scar over the brainstem with resolution of edematous changes (Figure 1). EEG at that time showed decrease in the epileptiform discharges. SSEPs showed no response from the cord and cortical area. EMG showed denervation. Visual evoked potentials and electroretinography were normal.

Clinical ethics and multidisciplinary team meeting was arranged to discuss withdrawal of care. Her treatment care was subsequently withdrawn and she passed away afterwards.

Discussion

HPeV infections most commonly are enteric and respiratory, but sepsis, meningitis, encephalitis and hepatitis have been described.² More severe diseases in the neonates comprising sepsis and encephalitis are associated with the recently emerged HPeV type 3.³ Almost all reported cases of HPeV encephalitis that were typed were due to type 3.^{4,5} In 1989, Koskiniemi et al presented a case of severe encephalitis caused by HPeV 1.⁶ Subsequently, fifteen more cases of HPeV encephalitis have been reported.^{4,5,7-9} Presenting symptoms are non-specific such as fever, irritability, seizure, apnoea and sepsis-like picture. MRI brain scans show particular patterns affecting white matter in internal capsule, periventricular area, corpus callosum, optic radiation and cerebral peduncles. Punctate lesions are also identified. The findings are derived from infection with different subtypes of human parechoviruses. Diagnosis is mainly by HPeV PCR in CSF. These children have variable prognosis (Table 1).

Its neurotropic property is further supported by Harvala et al who reported a predilection of HPeV type 3 to cause CNS infections in young infants.² Similar result was found by Benschop et al.¹⁰ It had been postulated that the use of different cellular receptors may be the reason explaining the neurotropic property of HPeV type 3.¹¹ The exact reason why neonates are susceptible to HPeV type 3 is not known. Ito et al found that only 56.5-73.9% of adults of child bearing age were seropositive for HPeV type 3, in contrast to 97% seropositivity of HPeV type 1.¹ Lack of protective transplacental antibodies may well pose a high risk to neonates. Prospective studies on the prevalence would be very useful in understanding the impact of this virus.

Diagnosis of viral encephalitis in the neonatal period can be challenging as the immune and inflammatory response especially in the CSF might not be present. Herpes simplex virus and cytomegalovirus are readily treated in neonatal CNS infection. Wolthers et al analysed 716 CSF samples in young children previously tested for enterovirus PCR. They found that the addition of a virus-specific PCR led to a 31% increase in detection of a viral cause of neonatal sepsis or central nervous system symptoms in children aged <5 years. They concluded that HPeV could be the second

Table 1 Demography, clinical and radiological features, diagnostic method and outcomes of the 15 cases reported in literature

	Gestation and age of onset	Presenting features	MRI findings	EEG finding	Diagnosis method	Outcome
Legacy 2002 ⁸	Not mentioned, 10 months	Fever, vomiting, generalised hypotonia, hyporeflexia	Not available	Not available	PCR in CSF	Good without further details
Verboon-Maciolek 2008 ⁹	28/40, 55 days	Fever, hypertonia, seizures, apnoea, rash	Extensive cystic leukomalacia; lack of myelination of the posterior limb of internal capsule on inversion recovery	Discontinuous normal voltage on aEEG (Amplitude-integrated EEG)	PCR in CSF	Cerebral palsy, epilepsy, cortical visual impairment at 6 years of age
	40/40, 6 days	Fever, irritability, seizures, apnoea, rash	Diffuse high signal intensity in periventricular white matter on T2SE; lactate present in the white matter in MRS; DWI (Diffusion weighted image) showed high signal intensity in periventricular white matter and corpus callosum	Continuous normal voltage on aEEG	PCR in stool	Hearing disability at 7 years of age
	39/40, 14 days	Fever, irritability, seizures, apnoea, rash	Diffuse high signal intensity in white matter, multiple punctate white matter lesions on T2, lactate present in the white matter in MRS. DWI showed high signal intensity in the periventricular white matter and corpus callosum; small infarction in left cerebral peduncle	Continuous normal voltage on aEEG	PCR in CSF	Normal at 4 years of age
	41/40, 6 days	Fever, irritability, seizures, apnoea, rash	Mild increase in signal intensity in the white matter, punctate white matter lesions on T2, DWI showed mild increase in signal intensity in the periventricular white matter; the corpus callosum and optic radiation	Continuous normal voltage in aEEG	PCR in CSF	Normal at 2 years of age
	25/40, 90 days	Seizures	Mild increase in signal intensity in the white matter T2; DWI showed high signal intensity in the periventricular white matter and the corpus callosum	Continuous normal voltage in aEEG	PCR in Blood	Normal cognition at 3 years of age, epilepsy
	32/40, 53 days	Fever, irritability, seizures, rash	Not available	Continuous normal voltage in aEEG	PCR in CSF	Normal at 18 months of age
	37/40, 7 days	Irritability, seizures, apnoea, diarrhoea	Diffuse high signal intensity in the periventricular white matter with multiple punctate lesions on T2, delay in myelination; DWI showed high signal intensity in the periventricular white matter, the corpus callosum, optic radiation, internal capsule, and cerebral peduncle	Discontinuous normal voltage in aEEG	PCR in CSF and blood	Suspect developmental delay at 18 months of age, mild distal hypertension

(continued on page 59)

Table 1 Demography, clinical and radiological features, diagnostic method and outcomes of the 15 cases reported in literature (cont'd)

	Gestation and age of onset	Presenting features	MRI findings	EEG finding	Diagnosis method	Outcome
	39/40, 7 days	Fever, irritability, seizures, apnoea	High signal intensity in the periventricular white matter on T2; DWI showed high signal intensity in the periventricular white matter, the corpus callosum and internal capsule, especially on the right side	Continuous normal voltage in aEEG	PCR in blood	Normal at 18 months of age
	39/40, 9 days	Lethargy, seizures, apnoea	Multiple punctate areas of T1 hyperintensity and T2 hypointensity in deep white matter; DWI showed restricted diffusion in periventricular white matter, deep white matter, corpus callosum, internal capsule, posterior thalami, optic radiations and cerebral peduncles	Continuous normal voltage in aEEG	PCR in CSF	Normal at 15 months of age
	39/40, 8 days	Fever, irritability, rash	Diffuse high signal intensity in the white matter; multipunctate white matter lesions on T2SE; DWI showed high signal intensity in the periventricular white matter and the corpus callosum	Not available	PCR in CSF	Normal at 9 months of age
van Zwol 2009 ⁵	38/40, 21 days	Fever, seizure, rash, hypertonia	Restricted diffusion in frontal and temporal white matter, cerebellar cortex, posterior limb of the internal capsule and genu corporis callosi, and anterior and mediodorsal thalamic subnuclei with the anterior thalamic radiation in the anterior limb of the internal capsule	Multiple epileptic discharges	PCR in CSF	Death on day 37 of life
	34/40, 35 days	Rash, seizure, respiratory distress and hypotonia	High signal on DWI symmetrical in hippocampus and fornix, unilateral in right caudate head and in a limited area of right frontal white matter; autopsy showed diffuse gliotic edema of white matter	Multiple epileptic discharges	PCR in CSF (type 3)	Death on day 53 of life
Levorson 2009 ⁴	Not mentioned, 13 days	Sepsis	White matter lesions in bilateral frontal region	Not available	PCR in CSF (type 3)	Good
Gupta 2010 ⁷	36/40, 7 days	Fever, poor feeding, seizures, apnoea	Extensive cystic white matter changes with volume loss, DWI not available	Encephalopathic with intermittent frontotemporal discharges	PCR in CSF	Suspect developmental delay at 6 months old, normal hearing

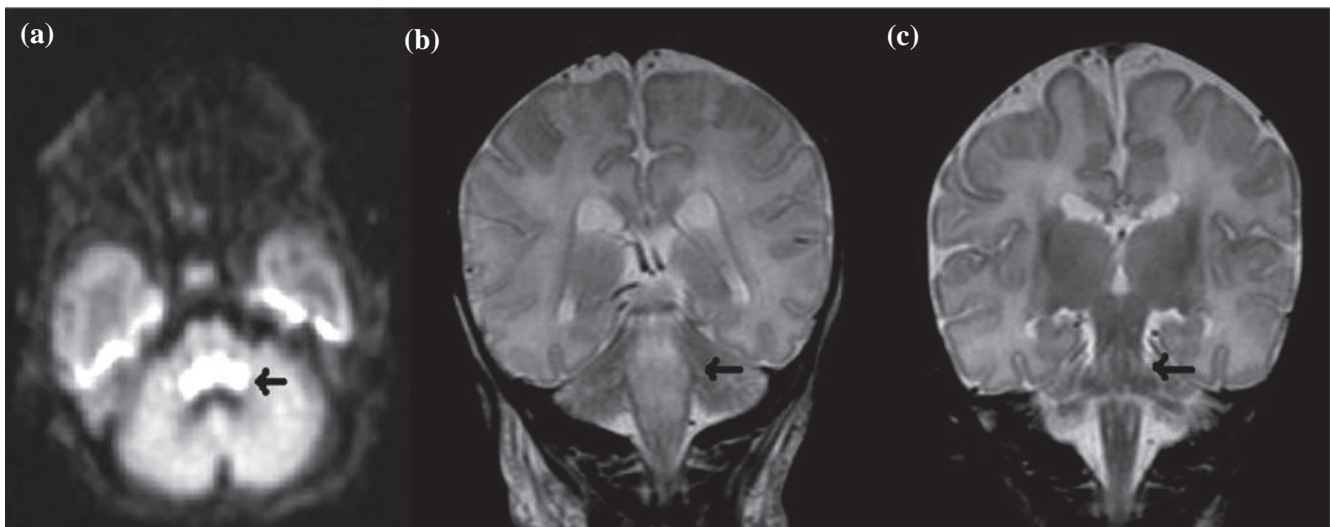


Figure 1 (a) Diffusion-weighted image of MRI on day 3 showing restricted diffusion over the brainstem. (b) Coronal image of MRI on day 3 showing oedematous change in brainstem and upper cervical cord. (c) Coronal image of MRI on day 23 showing gliotic changes in previous oedematous areas.

most common cause of viral sepsis and meningitis in young children.³ Early and accurate diagnosis can potentially lead to shortening the duration of antimicrobial and antiviral treatment.

Although there is no proven treatment for HPeV infection, accurate diagnosis and characterisation of HPeV infection is an important first step to a clearer understanding of its pathophysiology and eventually more effective treatments. From this case presented we would recommend earlier testing for HPeV by PCR in neonatal encephalitis of unknown origin.

References

1. Ito M, Yamashita T, Tsuzuki H, Takeda N, Sakae K. Isolation and identification of a novel human parechovirus. *J Gen Virol* 2004;85(Pt 2):391-8.
2. Harvala H, Wolthers KC, Simmonds P. Parechoviruses in children: understanding a new infection. *Curr Opin Infect Dis* 2010;23:224-30.
3. Wolthers KC, Benschop KS, Schinkel J. Human parechoviruses as an important viral cause of sepsislike illness and meningitis in young children. *Clin Infect Dis* 2008;47(3):358-63.
4. Levorson RE, Jantusch BA, Wiedermann BL, Spiegel HM, Campos JM. Human parechovirus-3 infection: emerging pathogen in neonatal sepsis. *Pediatr Infect Dis J* 2009;28:545-7.
5. Van Zwol AL, Lequin M, Aarts-Tesselaar C, et al. Fatal neonatal parechovirus encephalitis. *BMJ Case Reports* 2009;doi:10.1136/bcr.05.2009.1883.
6. Koskiniemi M, Paetau R, Linnavuori K. Severe encephalitis associated with disseminated echovirus 22 infection. *Scand J Infect Dis* 1989;21:463-6.
7. Gupta S, Fernandez D, Siddiqui A, Tong WC, Pohl K, Jungbluth H. Extensive white matter abnormalities associated with neonatal Parechovirus (HPeV) infection. *Eur J Paediatr Neurol* 2010;14:531-4.
8. Legay V, Chomel JJ, Fernandez E, Lina B, Aymard M, Khalfan S. Encephalomyelitis due to human parechovirus type 1. *J Clin Virol* 2002;25:193-5.
9. Verboon-Maciolek MA, Groenendaal F, Hahn CD, et al. Human parechovirus causes encephalitis with white matter injury in neonates. *Ann Neurol* 2008;64:266-73.
10. Benschop KS, Schinkel J, Minnaar RP, et al. Human parechovirus infections in Dutch children and the association between serotype and disease severity. *Clin Infect Dis* 2006;42:204-10.
11. Harvala H, Robertson I, Chieochansin T, McWilliam Leitch EC, Templeton K, Simmonds P. Specific association of human parechovirus type 3 with sepsis and fever in young infants, as identified by direct typing of cerebrospinal fluid samples. *J Infect Dis* 2009;199:1753-60.