

Clinical Quiz

What is the Diagnosis?

WKY CHAN, BCP WONG, TW FAN, PS YEUNG

Case History

An 18-month-old boy, with good past health, was admitted for persistent fever for 1 week. There was no obvious localizing symptom except passing loose stool for 2 times on the day of admission. On physical examination, vital signs were stable and abdominal examination showed a ballotable right kidney. Investigations showed white cell count $22 \times 10^9/L$, haemoglobin 10.2 g/dL, platelet count $583 \times 10^9/L$. Serum sodium was 135 mmol/L, potassium 4.6 mmol/L, urea 6.2 mmol/L and serum creatinine was 51 $\mu\text{mol/L}$. Urine microscopy showed WBC $>100/c.\text{mm}$ and RBC was negative. His nasopharyngeal aspirate for Influenza A was positive. An ultrasound abdomen was performed.

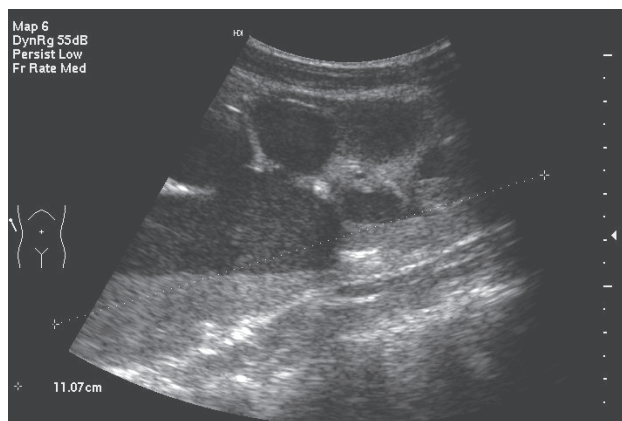


Figure 1

Question

1. Figure 1 showed the ultrasound of his right kidney and what did it show?
2. What further investigations would you perform?
3. What were shown in figure 2 and what was the diagnosis?
4. How would you manage the patient accordingly?

The clinical quiz was prepared by:

WKY CHAN
Department of Paediatrics, Queen Elizabeth Hospital

BCP WONG
Nuclear Medicine Unit, Queen Elizabeth Hospital

TW FAN
Department of Radiology and Imaging, Queen Elizabeth Hospital

PS YEUNG
St. Teresa's Hospital

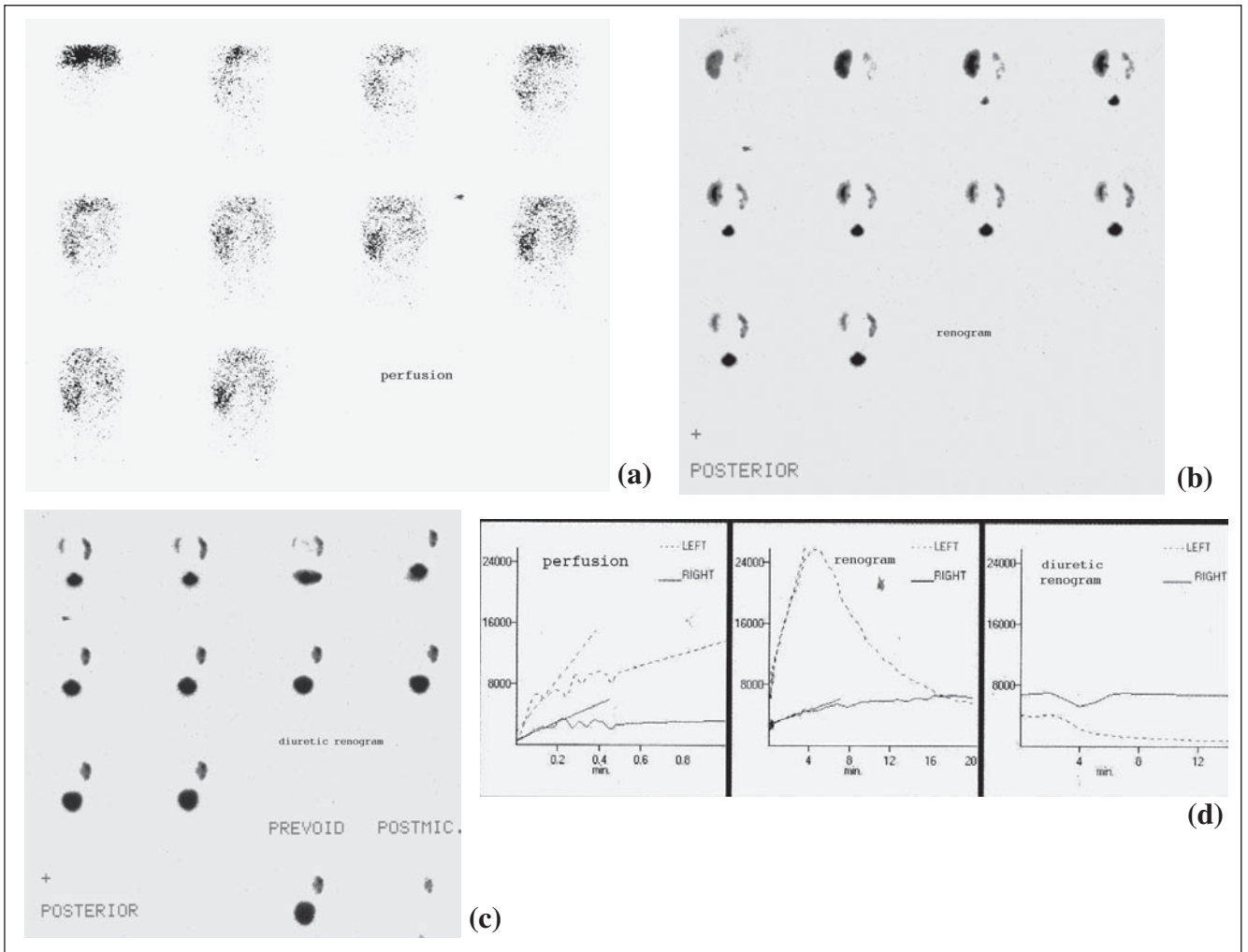


Figure 2

Answer to "Clinical Quiz" on Page 159

N.B. The Editors invite contributions of illustrative clinical cases or materials to this section of the journal.