

# Distinctive Phenotype in a Case of Ring Chromosome 22 with Features of 22q13.3 Deletion Syndrome

ACF LAM, KKS LAI, STS LAM

## Abstract

Chromosome 22q13.3 deletion syndrome (OMIM #606232) is a well defined clinical subtelomeric deletion syndrome characterised by severe expressive language delay, moderate mental retardation and somatic overgrowth without major internal organ anomalies and minimal cranio-facial dysmorphic features. We report a case of de novo ring chromosome 22 confirmed by FISH to have deletion 22q13.3, with typical features of 22q13.3 deletion syndrome; we emphasise the importance of cytogenetic analysis in children with severe speech delay, autism, hypotonia, developmental delay, accelerated growth and minimal cranio-facial dysmorphism.

## Key words

22q13.3; Autism; Severe expressive language delay; Subtelomeric deletion syndrome

## Introduction

Deletion 22q13.3 is a relatively common subtelomeric deletion syndrome, only second to 1p36.3 deletion,<sup>1</sup> in which affected individuals have absent to severe expressive language delay, moderate mental retardation, hypotonia, normal to somatic overgrowth, and minimal dysmorphic cranio-facial features.<sup>2</sup> These may include fair hair and skin, dolichocephaly, often commented to be good looking facial features with pointed chin and large ears. Distinctive behavioural characteristics constitute an important part of the syndrome that include autistic-like feature, increased pain tolerance, mouthing or chewing non-food objects and sleep disturbance.<sup>2,3</sup>

The diagnosis of 22q13.3 syndrome is confirmed by routine cytogenetic studies and/or FISH (Fluorescence in situ hybridisation) studies (for subtle deletions) with

majority of patients having simple terminal deletion while a minority having deletions resulting from an unbalanced translocation or other structural rearrangement such as a ring chromosome. Majority of 22q13.3 deletions occur de novo. The minimum critical region of deletion overlap for the 22q13.3 syndrome is a 100-kb region overlapping *SHANK3*, the candidate gene responsible for neurological deficits in 22q13.3 syndrome. *SHANK3* is located within 200-kb of the chromosome 22 telomere. It is expressed in cerebral cortex and cerebellum; and codes for structural protein that is involved in excitatory postsynaptic density which in turn may affect synapse formation and function.<sup>4</sup> Subtelomeric FISH probes are commercially available FISH probes, and they are currently gold standard for detecting deletion of 22q13.3. While more commonly, diagnosis of deletion 22q13.3 was ascertained as an incidental finding during FISH studies for other microdeletion syndromes; namely Velocardiofacial syndrome, where the region highlighted by the control probes 22q13 was found to be absent.<sup>5</sup>

The true incidence of this clinically recognisable entity, deletion 22q13.3 syndrome is unknown. The syndrome is underdiagnosed because patients have minimal facial dysmorphism and often have no internal organ anomalies that are characteristic of subtelomeric deletions.<sup>6</sup> Secondly, chromosomal abnormalities are often not suspected when patients presented with only hypotonia in neonatal period;

Clinical Genetic Service, Department of Health, Hong Kong, China

ACF LAM (林傳發) MRCPCH  
KKS LAI (黎強新) BSc  
STS LAM (林德深) FHKAM

Correspondence to: Dr STS LAM

Received July 3, 2006

or autism with severe delayed speech in childhood. Even when chromosome studies were ordered, the deletion may not be cytogenetically visible. All these contributed to the apparent low incidence of the syndrome.

We report a case of ring chromosome 22 confirmed by FISH to have deletion 22q13.3, who presented with typical features of 22q13.3 deletion syndrome. We emphasise the importance of cytogenetic analysis and high index of clinical suspicion in children with severe speech delay, autism, hypotonia, developmental delay, accelerated growth and minimal facial dysmorphism.

### Subject, Method and Results

Proband was a 7-year-old male, born to non-consanguineous parents at term with birth weight 3.23 kg. He was the only child in the family and there was no family history of recurrent miscarriage or mental retardation. Developmental delay was noted at 10 months of age. Subsequent milestones revealed sitting at 10 months, walked at 22 months and remained no speech at 22 months. He was referred to Clinical Genetic Service at 3 years of age for developmental delay. On examination, his head circumference was 49.5 cm (25-50%), body weight 15.7 kg (75-90%), height 98 cm (75%). He had fair hair and skin, hypotonia, minimal cranio-facial dysmorphism, no speech; and autistic features include poor eye contacts, ecolalia and repetitive non-intentional behaviour. Otherwise proband was healthy. At aged 4 years, his head circumference was 50.5 cm (50%), body weight 18.3 kg (90%), height 105 cm (75%). At 5 years of age, his head circumference was 51 cm (50%), body weight 20.4 kg (90%), height 111 cm (75%). At 6 years old, his head circumference was 51.5 cm (50%), body weight 22.5 kg (75-90%), height 118.2 cm (90%). MRI of the brain revealed no abnormality. Family history was unremarkable.

#### Cytogenetic Study

Standard and high resolution G banding chromosomal analyses were performed on metaphases spread obtained from proband and his parents' peripheral blood lymphocytes.

LSI DiGeorge N25 (D22S75) region probes from VYSIS were used: 22q11.2 LSI N25 probe and 22q13 LSI ARSA probe. Metaphase spreads were prepared from patient's peripheral blood lymphocyte cultures. The probes were denatured and hybridised according to the manufacturer's instructions. Chromosomes were counterstained with DAPI after the post-hybridisation wash. Preparations were then

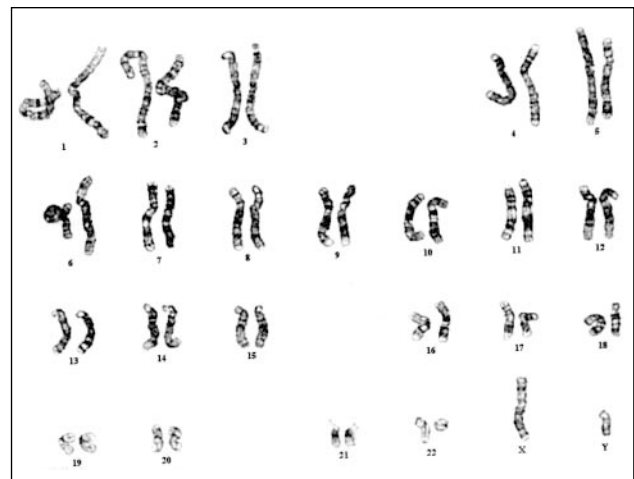examined using a fluorescence microscope with appropriate filters.

Examination of 15 metaphases preparation revealed simple ring chromosome in all cells. Karyotype result was "46,XY,r(22)(p11.2q13.3)" (Figure 1). Fluorescence in situ hybridisation study of all 9 cells showed "ish del(22)(q13q13)" (Figure 2). Parental karyotypes were normal.

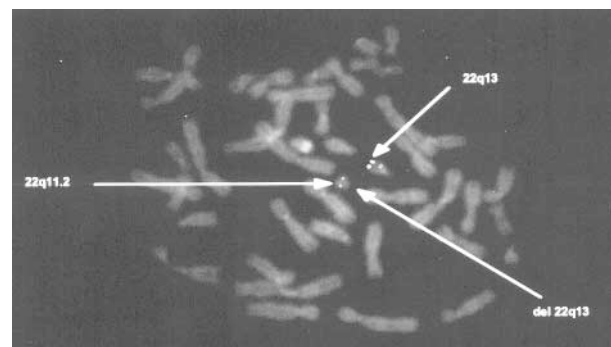
Parental consent for publication was kindly given and signed.

### Discussion

Ring chromosomes are formed as a result of breakage and reunion in the distal p and q arms with accompanying loss of genetic materials in these involved regions. In ring chromosome 22, loss of p-arm and satellite materials have minimal clinical consequences. Instead, the size of distal deleted q-arm segment affects the overall phenotype. There



**Figure 1** Karyotype of proband showing ring 22.



**Figure 2** FISH study showing deletion 22q13.3.

is a positive correlation between the severity of the phenotype and the size of the deletion.<sup>7</sup>

The phenotype of ring chromosome 22 is variable. The variability may partly be explained by instability of ring 22 during mitosis, presence of supernumerary marker and/or duplication of any segment involving chromosome 22; and the level of mosaicism in individual cases reported.<sup>8,9</sup> Mitotic instability, although theoretically possible, appears to be very rare in chromosome 22 rings and is unlikely to be of major significance to the ring 22 phenotype.<sup>2,7</sup> This is evident in our case in which a simple ring 22 was seen in all cells examined (Figure 1).

There are some overlapping clinical features between ring 22, simple terminal deletion and derivative chromosome 22 causing subtelomeric deletion syndromes which include, the presence of moderate to severe mental retardation, severe speech delay, hypotonia, and normal to accelerated growth.<sup>10</sup> Other reported features include growth retardation (20%) microcephaly (30%), and rare reports of associated internal organ anomalies.<sup>2,11</sup> In general, major malformations are not common association in ring 22, as in their counterpart simple 22q13.3 deletion. In fact, many reports of uncomplicated ring chromosome 22 showed similar features to 22q13.3 deletion syndrome as in our present case.

Deletion 22q13.3 is a well delineated subtelomeric deletion syndrome. The true incidence is believed to be underestimated since these cases are often not referred to clinical geneticists as they are not thought of as having chromosomal abnormality; and that these deletions are not visible on routine cytogenetic analysis. Future application of new methodologies such as Multiplex Ligation-dependent Probe Amplification (MLPA) and Subtelomeric FISH screening may reveal more affected cases.<sup>6</sup> A high index of clinical suspicion in children with severe speech delay, autism, hypotonia, developmental delay, accelerated growth and minimal facial dysmorphism should prompt physicians to seek genetic consultation and counselling. Majority of cases occur de novo as in our case in which the

recurrence risk is low. However in cases of parental chromosomal abnormality, the recurrence risk may be significant.

## References

1. Heilstedt HA, Ballif BC, Howard LA, Kashork CD, Shaffer LG. Population data suggest that deletions of 1p36 are a relatively common chromosome abnormality. *Clin Genet* 2003; 64:310-6.
2. Jeffries AR, Curran S, Elmslie F, et al. Molecular and phenotypic characterization of ring chromosome 22. *Am J Med Genet A* 2005;137:139-47.
3. MacLean JE, Teshima IE, Szatmari P, Nowaczyk MJ. Ring chromosome 22 and autism: report and review. *Am J Med Genet* 2000;90:382-5.
4. Boeckers T, Kreutz M, Winter C, et al. Proline-rich synapse-associated protein-1/cortactin binding protein 1 (ProSAP1/CortBP1) is a PDZ-domain protein highly enriched in the postsynaptic density. *J Neurosci* 1999;19:6506-18.
5. Praphanphoj V, Goodman BK, Thomas GH, Raymond GV. Cryptic subtelomeric translocations in the 22q13 deletion syndrome. *J Med Genet* 2000;37:58-61.
6. Lam AC, Lam ST, Lai KK, Tong TM, Chau TC. High rate of detection of subtelomeric aberration by using combined MLPA and subtelomeric FISH approach in patients with moderate to severe mental retardation. *Clin Biochem* 2006;39:196-202.
7. Luciani JJ, de Mas P, Depetris D, et al. Telomeric 22q13 deletions resulting from rings, simple deletions, and translocations: cytogenetic, molecular, and clinical analyses of 32 new observations. *J Med Genet* 2003;40:690-6.
8. Frizzley JK, Stephan MJ, Lamb AN, et al. Ring 22 duplication/deletion mosaicism: clinical, cytogenetic, and molecular characterisation. *J Med Genet* 1999;36:237-41.
9. Chen CP, Chern SR, Chang TY, et al. Prenatal diagnosis of mosaic ring chromosome 22 associated with cardiovascular abnormalities and intrauterine growth restriction. *Prenat Diagn* 2003;23:40-3.
10. Phelan MC, Rogers RC, Saul RA, et al. 22q13 deletion syndrome. *Am J Med Genet* 2001;101:91-9.
11. Delcan J, Orera M, Linares R, Saavedra D, Palomar A. A case of ring chromosome 22 with deletion of the 22q13.3 region associated with agenesis of the corpus callosum, fornix and septum pellucidum. *Prenat Diagn* 2004;24:635-7.