

Clinical Quiz

What is the Diagnosis?

CY YEUNG

Case 1 (Figure 1)

5 1/2-month-old girl, presented with acute inspiratory stridor x 1 day; high swinging temperature, refused feeding x 2 days; toxic, cyanotic, drooling of saliva, fretful; fullness around upper neck + enlarged tender lymph nodes.

- List 3 most important differential diagnoses before you see the radiograph.
- What are the relevant findings in this radiograph?
- What is the diagnosis?

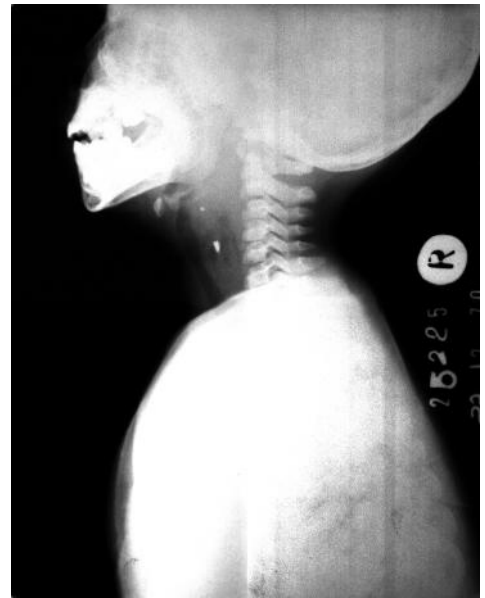

Figure 1.

Case 2 (Figure 2)

8-month-old boy presenting with features of vague ill-health with intermittent irregular bowel habits and vomiting for 4+ weeks; fever x 3+ weeks. When examined: Abdomen: distended with gases + some ascites; doughy feeling with mild rebound tenderness; patchy gut-matted together.

- List 3 most important differential diagnoses before you see the CAT scan.
- What relevant investigations would you do before you see the CAT scan results?
- What are the relevant findings in these CT-Abdomen pictures?
- What is the diagnosis?

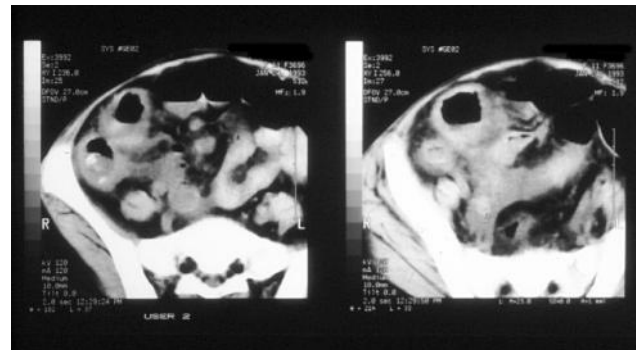


Figure 2.

Answer to "Clinical Quiz" on Page 45

N.B. The Editors invite contributions of illustrative clinical cases or materials to this section of the journal.