

Case Report

A New Case - Heterozygote *PACS1* Mutation in a Patient with Schuurs-Hoeijmakers Syndrome and a Left Duplex Kidney: Case Report

B DILBER, E ARSLAN ACAR, AH CEBI, A CANSU

Abstract *PACS1* is a rare form of monogenic disorder characterised by intellectual disability, developmental delay, and mild distinctive facial features. The typical facial features include a low hairline on the forehead, eyes that are spaced far apart and slanting downwards, thick eyebrows that may be connected to each other, long eyelashes, large ears that are set low on the head, and gaps between the teeth. Diagnosis is made through a genetic analysis, particularly by whole exome sequencing. Although renal abnormalities are rarely seen in such patients, we present an atypical case of a 33-month-old girl with a left duplex kidney.

Key words Down-like face; Duplex kidney; *PACS1*; Typical facial features

Introduction

PACS1 gene is found on the long arm of the chromosome 11 (11q13.1-13.2). The mutations showing autosomal dominant inheritance in this gene are known to cause Schuurs-Hoeijmakers syndrome. For the first time, Schuurs-Hoeijmakers et al diagnosed *PACS1* as a *de novo* mutation in two boys who had similar findings and no cognation. The findings included similar typical facial appearance, intellectual and motor disability, and cryptorchidism.¹ A *de novo* c.607C>T (p.R203W) mutation was detected in both boys and their clinical appearance were highly similar. In 2014, three other patients with similar findings and

PACS1-associated symptoms were described by Gadzicki et al.²

The only known cause of Schuurs-Hoeijmakers syndrome is the *PACS1* mutation. Typical manifestations of this syndrome include intellectual disability, characteristic facial features such as a mouth with down-turned corners, seizures, and cerebral abnormalities. A *de novo* c.607C>T (p.R203W) mutation is typically seen in *PACS1*. Also, Miyake N et al reported a *de novo* missense *PACS1* (c.608G>A (p.R203Q) mutation.³ In the case presented in this study, a heterozygous missense c.607C>T (p.R203W) mutation was detected in the *PACS1* gene and the patient was diagnosed with whole exome sequencing (WES). Additionally, the patient was detected with a left duplex kidney, which is a rare occurrence in such patients.

Department of Pediatric Neurology, Karadeniz Technical University, Trabzon, Turkey

B DILBER MD
E ARSLAN ACAR MD
A CANSU Prof.

Department of Genetic, Karadeniz Technical University, Trabzon, Turkey

AH CEBI MD

Correspondence to: Dr B DILBER
Email: beriltem@gmail.com

Received May 29, 2019

Case Presentation

A 33-month-old girl with a body weight of 12.8 (10th-25th percentile), height of 90 cm (10th percentile), and a head circumference of 48 cm (10th percentile) presented to the paediatric neurology clinic due to speech retardation and atypical facial appearance. Neuromotor development of the patient was retarded and it was revealed that she could hold her head steady at 4 months, sat without support at 18

months, started to walk at 26 months. Although the patient produced only four meaningful words, she was friendly and good-humoured. Her IQ was revealed to be 54 according to the Denver Developmental Screening Test (DDST). She was the first living child delivered at the third pregnancy of her mother who was 27 years old during the time of delivery. It was also revealed that the mother had been followed up due to oligohydramnios throughout the gestational period and her father was a 32-year-old healthy individual. The parents had no consanguineous relationship. Patient history revealed that the patient had been monitored under mechanical ventilation after birth due to neonatal meconium aspiration syndrome. Moreover, she experienced apnoeic seizures three times in the neonatal period, followed by a focal seizure on her right arm at the age of 3 months. After the age of two, her antiepileptic treatment was discontinued when she had no more seizures. Physical examination revealed hypertelorism, mild ptosis, a large mouth, depressed and wide nasal bridge, long philtrum, flat eyebrows, eyelids drooping downwards, prominent ears, thin upper lip, overlapping toes in the right foot, and pectus excavatum (Figure 1). Additionally, a grade 1/6 systolic ejection murmur was heard. Other system examinations were normal and biochemical analyses were unremarkable. No immunodeficiency was found. A patent foramen ovale (PFO) was detected on electrocardiography (ECG). Renal ultrasonography (US), which was performed due to the presence of recurrent urinary tract infections, revealed a left duplex kidney. Cranial magnetic resonance imaging (MRI) scan was normal and electroencephalography (EEG) was unremarkable. WES revealed a heterozygous *de novo* missense c.607C>T (p.R203W) mutation in the *PACSI1* gene.

Discussion

Abnormal migration of nerve cells resulting from the replacement of arginine by tryptophan in the furin-binding region is considered to play a role in the etiopathogenesis of *PACSI1*, and similar facial findings are explained by zebrafish research.⁴ However, the presence of similar facial features in other symptoms including Baraitser-Winter syndrome, Cornelia de Lange syndrome, Mowat-Wilson syndrome, and Kabuki syndrome complicates the diagnosis of *PACSI1* mutations. This challenge can be eliminated by the use of WES analysis, which can also detect the abnormalities accompanying these facial features.

The *PACSI1* mutation detected in our patient was characterised by intellectual disability, prominent craniofacial characteristics (hypertelorism, mild ptosis, a large mouth, depressed and wide nasal bridge, long philtrum, flat eyebrows, eyelids drooping downwards, prominent ears, and thin upper lip), psychomotor retardation, mild-to-moderate speech retardation, hypotonia, seizures, structural malformations (heart, brain, eyes, kidneys, and bones), and additional congenital anomalies (Tables 1 & 2). The WES analysis performed in our patient detected a heterozygous missense c.607C>T (p.R203W) mutation in the *PACSI1* gene. This mutation was also shown to be heterozygous in the DNA sequencing analysis performed with the Sanger method. Additionally, the parents were also examined and were found to be normal.

Schuurs-Hoeijmakers et al, in their series of 19 cases aged 2-21 years, found typical facial anomalies in all patients as well as different abnormalities including cardiac abnormalities in 10 patients and renal problems in three patients.⁴ Additionally, almost half of the patients

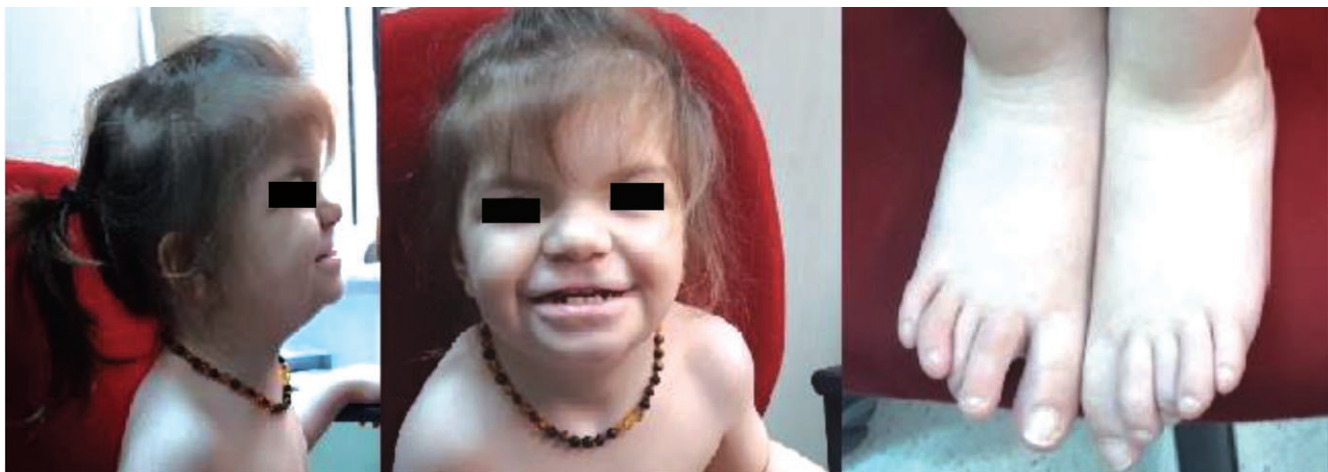


Figure 1 Clinical photo showing hypertelorism, mild ptosis, a large mouth, depressed and wide nasal bridge, long philtrum, flat eyebrows, eyelids drooping downwards, prominent ears, thin upper lip, overlapping toes in the right foot, and pectus excavatum.

presented with gastrointestinal problems such as severe feeding, swallowing, and reflux problems. Renal abnormality was seen in only three cases and two of them had right renal duplex anomaly and urethral diverticulum. No vesicourethral reflux was observed.⁴ In our case, however, had a left duplex kidney and grade IV vesicoureteral reflux. We consider that advanced genetic analyses are helpful for the establishment of diagnosis in these patients, as was in our case. Accordingly, WES analysis appears to be ideal option in the diagnosis of these patients.

Conclusion

Whole exome sequencing (WES) appears to be an ideal method for the diagnosis of patients with moderate intellectual disability, prominent speech retardation, and

non-persistent seizures, particularly of patients with similar facial appearance. Patients with *PACSI* mutation may rarely present with renal abnormalities, most of which are treatable. The use of social media platforms (e.g. *PACSI* groups) by the parents of children diagnosed with *PACSI* mutation could be helpful for raising awareness and eliminating concerns among these patients and their parents. Accordingly, by presenting the current case, we aimed to raise awareness among the parents of children with a *PACSI* mutation by emphasizing that a *PACSI* mutation could be present in syndromic patients with intellectual disability and similar facial appearance and that there could be additional abnormalities in such patients that may require clinical follow-up.

Conflict of Interest

All the authors declare no conflict of interest for this study.

Table 1 Typical facial appearance findings of *PACSI* mutation

Facial appearance
Arched eyebrows
Hypertelorism with downslanting palpebral fissures
Long eye lashes
Ptosis (in some)
Low set and simple ears
Bulbous nasal tip
Wide mouth with downturned corners
Thin upper lip with an unusual "wavy" profile
Fat philtrum
Diastema of the teeth

References

1. Schuurs-Hoeijmakers JH, Oh EC, Vissers LE, et al. Recurrent de novo mutations in *PACSI* cause defective cranial-neural-crest migration and define a recognizable intellectual-disability syndrome. *Am J Hum Genet* 2012;91:1122-7.
2. Gadzicki D, Döcker D, Schubach M, et al. Expanding the phenotype of recurrent de novo variant in *PACSI* causing intellectual disability. *Clin Genet* 2015;88:300-2.
3. Miyake N, Ozasa S, Mabe H, et al. A novel missense mutation affecting the same amino acid as the recurrent *PACSI* mutation in Schuurs-Hoeijmakers syndrome. *Clin Genet* 2018;93:929-30.
4. Schuurs-Hoeijmakers JH, Landsverk ML, Foulds N, et al. Clinical delineation of the *PACSI*-related syndrome-Report on 19 patients. *Am J Med Genet A* 2016;170:670-5.

Table 2 Major organ involvement for Schuurs-Hoeijmakers syndrome

Growth & Feeding	Microcephaly	Failure to thrive	Oral aversion	Reflux G-tube
Neurodevelopmental features	Developmental delay/ intellectual disability	Language development	Temper tantrums/ aggression	
Neurological disorder & Behaviour seizures	Hypotonia	Structural brain abnormalities	Dysmorphic facial features	Autism spectrum disorder
Cerebral imaging				
Skeletal abnormalities	Pectus excavatum	Scoliosis	Clinodactyly of 5th finger	Abnormal skull shape
Congenital malformations	ASD/VSD	Colobomata Cryptorchidism	Single palmar crease	Kidney abnormality