

## Case Report

# Two Cases of Paediatric Essential Thrombocythaemia with Calreticulin Gene Mutation

MMH CHENG, KFS LEUNG, ASC LING

### Abstract

Essential thrombocythaemia is a rare entity among the various paediatric haematological disorders. We report two symptomatic cases admitted into a regional hospital in Hong Kong. Both patients were found to have mutated Calreticulin gene at different sites. One patient has a positive family history. The patients were given anti-platelet and cytoreductive agents, as well as interferon-alpha with good clinical outcome. Our report highlights the clinical features and treatment strategies of this myeloproliferative disorder, emphasizing on the contribution of molecular investigations in the diagnostic pathway.

### Key words

Calreticulin; Essential thrombocythaemia; Interferon-alpha; Myeloproliferative disorders

### Introduction

Essential thrombocythaemia (ET) is a chronic myeloproliferative disorder characterised by persistent thrombocytosis. It is very rare in the paediatric population, with an estimated incidence of one per 10,000,000 children (less than 14 years old) per year. Age of presentation ranged between 0.2 to 19 years. Most patients remain asymptomatic and thrombocytosis is often detected on routine blood check.<sup>1</sup> Here, we report two patients with newly diagnosed ET with different degree of severity at presentation.

**Department of Paediatrics and Adolescent Medicine, Princess Margaret Hospital, 2-10 Princess Margaret Hospital Road, Lai Chi Kok, Kowloon, Hong Kong SAR, China**

MMH CHENG (鄭文軒) *MRCPCH, FHKCPaed, FHKAM(Paed)*

ASC LING (凌紹祥) *MRCP(UK), FHKCPaed, FHKAM(Paed)*

**Department of Pathology, Princess Margaret Hospital, 2-10 Princess Margaret Hospital Road, Lai Chi Kok, Kowloon, Hong Kong SAR, China**

KFS LEUNG (梁鳳珊) *FHKCPath, FHKAM(Pathology), MPH(HK)*

**Correspondence to:** Dr MMH CHENG

Email: [cmhmark@gmail.com](mailto:cmhmark@gmail.com)

Received February 3, 2018

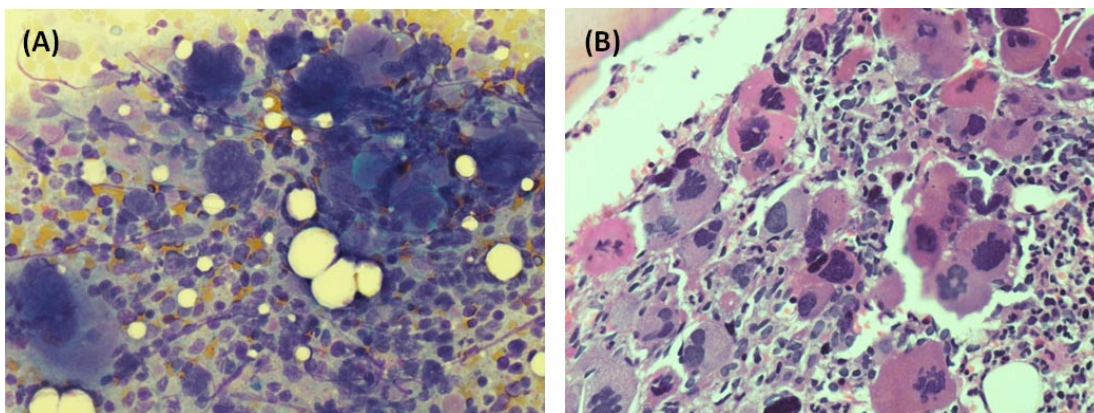
### Case Report

A 13-year-old Chinese boy presented to Princess Margaret Hospital, Hong Kong for sudden onset of headache, vomiting and left-sided weakness. He also had photophobia and visual aura in the form of flashes. He remained conscious and alert but was unable to walk. He enjoyed good past health. The patient's mother reported that she was followed up for myelofibrosis by haematologists. There was no history of myeloproliferative disease in the grandparents. On physical examination the patient had left hemiplegia. Power over left upper limbs (4/5) was better than lower limbs (3/5). There was no hepatosplenomegaly. Examination of other systems was unremarkable. Ophthalmological assessment did not reveal any significant abnormality. Complete blood count showed marked thrombocytosis ( $2326 \times 10^9/L$ ) and leukocytosis ( $41 \times 10^9/L$ ). Haemoglobin was 12.4 g/dL. Peripheral blood smear showed giant platelets, occasional myelocytes and blast cells. Coagulation profile, liver and renal functions were normal. Plain computed tomography (CT) of the brain was normal. However, magnetic resonance imaging (MRI) of the brain showed multiple bilateral cerebral infarcts, most prominent over the left occipital and right frontal regions. Bone marrow examination showed hypercellular marrow with granulocytic and

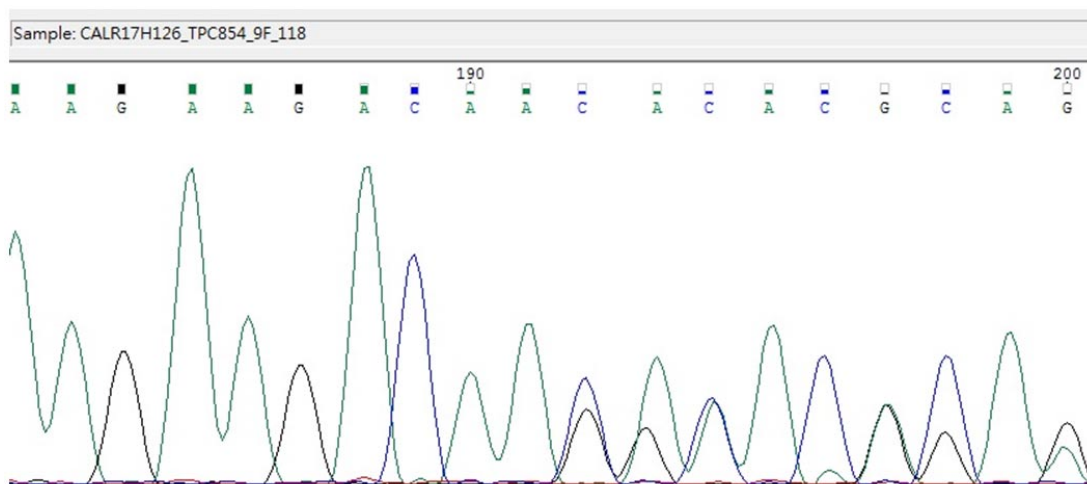
megakaryocytic hyperplasia (Figure 1). Cytogenetic study was normal and the patient was negative for BCR/ABL or JAK2 V617F mutation. A diagnosis of ET complicated by cerebral infarcts was made. Further genetic study by polymerase chain reaction and direct sequencing method revealed a 4 bp deletion at exon 9 of Calreticulin (CALR) gene (Figure 2). The same mutation was detected in patient's mother in 2016. In 2010, the patient's mother was found to have thrombocytosis at the age of 31, when she presented to her general practitioner for malaise. She was subsequently diagnosed with myelofibrosis and was

put on aspirin and hydroxyurea. She never developed any thrombotic or haemorrhagic complications. Germline mutation analysis using buccal mucosa and hair follicles demonstrated that the CALR mutations of the patient and his mother were somatically acquired.

The patient was started on Aspirin 100 mg on the second day of admission for acute cerebral infarcts. He was initially put on hyperhydration to lower his platelet count. As there was persistent thrombocytosis with platelet count higher than  $2000 \times 10^9/L$ , he was started on hydroxyurea on the second week of admission. Platelet count gradually



**Figure 1** Bone marrow aspirate (A) shows hypercellular marrow with granulocytic hyperplasia and marked megakaryocytic hyperplasia in clusters, with many large and hyperlobulated ones seen. Megakaryocytes are markedly increased in trephine biopsy (B). Many appear in tight clustering, with some hyperlobulated and hyperchromatic ones present. Para-trabecular clusters of megakaryocytes are also seen.



**Figure 2** CALR exon 9 mutation was analysed by PCR and direct sequencing method using peripheral blood sample. A 4bp deletion at c.1122\_1125delGAAA is detected at exon 9 of CALR (p.K374fs\*55) gene (RefSeq: NM\_004343.3). The patient has the same 4bp deletion as seen in his mother, and this frameshift mutation in exon 9 of the CALR gene has been previously reported in the literature.

dropped below  $1000 \times 10^9/L$  one month later. Von Willebrand factor studies revealed absent ristocetin cofactor activity (VWF:RCo), markedly reduced VWF:RCo/VWF:Ag ratio at zero and preserved FVIII:C/VWF:Ag ratio (0.68). Platelet aggregation study showed diminished aggregation with high dose ristocetin and absent response to low dose ristocetin. The results were suggestive of von Willebrand disease Type 2 due to extreme thrombocytosis. After consideration, aspirin was continued as there was established thrombosis and no evidence of clinical bleeding. The patient made a full neurological recovery on discharge. Three months after diagnosis, the patient was started on pegylated interferon-alpha to replace hydroxyurea in view of the potential risks of subfertility and development of second malignancies in long-term use. The platelet count and laboratory abnormality of Type 2 von Willebrand disease normalised and the patient remained asymptomatic.

The second patient was a 17-year-old teenage girl with good past health presenting with headache, dizziness and vomiting for one week. There was transient visual disturbance involving the left temporal field of vision. Physical examination including neurological examination was normal. Plain CT scan of the brain was normal. Complete blood count showed thrombocytosis ( $1550 \times 10^9/L$ ) and mild leukocytosis ( $9.9 \times 10^9/L$ ). Giant platelets were seen in the blood smear. Bone marrow examination showed normocellular marrow with markedly increased megakaryocytes, some in cluster and hyperlobulated. Genetic study detected Type I CALR mutation, a 52-bp deletion at exon 9 (p.L367fs\*46). The patient was started on aspirin and pegylated interferon-alpha. Von Willebrand factor assays also showed results consistent with Type 2 von Willebrand disease. The patient remained asymptomatic afterwards and the platelet count was in decreasing trend. Screening of the complete blood count of the parents and sibling revealed no abnormalities.

## Discussion

Approximately one-third of paediatric patients with ET presented with headache or paraesthesia.<sup>2</sup> Other clinical manifestations are mostly caused by microcirculatory disturbances. These include dizziness, syncope, visual disturbance, digital ischaemia, vomiting and abdominal pain. Splenomegaly is present in one-third of patients. Hepatomegaly is uncommon.<sup>1,2</sup> Thrombotic complications such as cerebrovascular accidents, myocardial infarction

and lower extremity venous thrombosis are rare in children but contribute significantly to the morbidity and mortality in adults with ET. Extreme thrombocytosis (platelet  $>1000 \times 10^9/L$ ) may be associated with bleeding tendency due to acquired von Willebrand syndrome (AVWS). This is characterised by the loss of large von Willebrand factor multimers and resembles a functional defect, as evident by abnormal ristocetin cofactor activity (VWF:RCo). Von Willebrand factor antigen (VWF:Ag) and Factor VIII levels may still be within normal ranges. The underlying mechanism of AVWS is unknown.<sup>3</sup> Major haemorrhages are reported in up to 10% of adult patients but are rarely reported in children.<sup>1</sup>

The 2008 World Health Organization (WHO) diagnostic criteria for ET required the presence of persistent thrombocytosis, bone marrow abnormalities, exclusion of other malignant or reactive causes of thrombocytosis, and the detection of clonal marker such as JAK2V617F (optional). After the discovery of the CALR mutation in 2013, it was subsequently found to be present in 67% of JAK2- and MPL-negative adults with ET. In the revised version of WHO diagnostic criteria for myeloproliferative neoplasms published in 2016, the presence of CALR mutation was included as a major diagnostic criterion for the diagnosis of ET.<sup>4</sup> The CALR gene is located in the short arm of chromosome 19. Mutations are in the form of insertions or deletions within exon 9 of the CALR gene. The pathogenetic mechanism of thrombocythaemia involves activation of the thrombopoietin receptor (TpoR/MPL) by CALR mutants. Giona, et al. detected various types of CALR mutation in 23% of a cohort of 34 paediatric ET patients.<sup>5</sup> The inheritance patterns of familial myeloproliferative diseases were largely heterogeneous. To date, no specific mode of inheritance has been described for CALR-mutated ET. It was observed in a previous study that although familial cases exist, CALR mutations were somatically acquired events in patients with ET.<sup>6</sup> Given the uncertain inheritance pattern, the chance of future offspring having the same disease is uncertain. When compared to JAK2V617F-positive ET, adult patients with CALR-mutated ET tend to present at a younger age, have higher platelet counts, lower leukocyte counts and haemoglobin, and lower thrombotic risk.<sup>7</sup>

The main goals in the management of ET are to prevent thrombotic or haemorrhagic complications and to improve vasomotor symptoms. Treatment of ET in adults is individualised and adopts a risk-based strategy. Patients with history of thrombosis or over 60 years with JAK2 mutation are considered to have high-risk disease.<sup>8</sup> In

general, anti-platelet agent such as aspirin is recommended for low-risk patients for alleviating microvascular disturbances and preventing thrombosis. Hydroxyurea has been shown to prevent thrombosis in high-risk patients and is the first-line treatment in combination with aspirin. Controversies remained regarding the potential leukaemogenicity of this cytoreductive agent. Pegylated interferon-alpha has been shown to induce haematologic remissions and reduce mutant CALR allele burden in patients with ET. Haematological response could be maintained for more than 60 months after discontinuation of interferon.<sup>9</sup> In a study on 31 patients with CALR-mutated ET, two patients achieved complete molecular remission. Their mutant clones dropped to an undetectable level after 8 and 20 months of treatment with pegylated-interferon respectively. The mutant allele was reduced, yet still detectable in 17 patients.<sup>10</sup> There is currently no recommendation on monitoring of mutation burden or the duration of interferon treatment. Side effects of interferon-alpha including neutropenia, deranged liver enzymes, fatigue and diarrhea are reported but are generally well tolerated at a dosage of 90 microgram weekly. Generally, paediatric ET patients will remain stable as long as their platelet count are controlled with no thrombosis or bleeding complications. However, they should be monitored for disease evolution into myelofibrosis or leukaemia requiring consideration of haematopoietic stem cell transplant.

In summary, we described two adolescent patients with CALR-mutated ET, one of them being a familial case. Both patients had extreme thrombocytosis and acquired von Willebrand syndrome. They achieved good clinical outcome after treatment with hydroxyurea and the subsequent use of pegylated interferon-alpha. These two cases featured the relatively new CALR mutation and its diagnostic value in ET. They also provided an insight into the wide spectrum of presentation and complications associated with the condition.

## Conflict of Interest

We declare that we have no conflict of interest.

## References

1. Fu R, Zhang L, Yang R. Paediatric essential thrombocythaemia: clinical and molecular features, diagnosis and treatment. *Br J Haematol* 2013;163:295-302.
2. Giona F, Teofili L, Moleti ML, et al. Thrombocytopenia and polycythemia in patients younger than 20 years at diagnosis: clinical and biologic features, treatment, and long-term outcome. *Blood* 2012;119:2219-27.
3. Elliott MA, Tefferi A. Thrombosis and haemorrhage in polycythaemia vera and essential thrombocythaemia. *Br J Haematol* 2005;128:275-90.
4. Arber DA, Orazi A, Hasserjian R, et al. The 2016 revision to the World Health Organization classification of myeloid neoplasms and acute leukemia. *Blood* 2016;127:2391-405.
5. Giona F, Teofili L, Capodimonti S, et al. CALR mutations in patients with essential thrombocytopenia diagnosed in childhood and adolescence. *Blood* 2014;123:3677-9.
6. Rumi E, Harutyunyan AS, Pietra D, et al. CALR exon 9 mutations are somatically acquired events in familial cases of essential thrombocytopenia or primary myelofibrosis. *Blood* 2014;123:2416-9.
7. Rotunno G, Mannarelli C, Guglielmelli P, et al. Impact of calreticulin mutations on clinical and hematological phenotype and outcome in essential thrombocytopenia. *Blood* 2013;123:1552-5.
8. Tefferi A, Barbui T. Polycythemia vera and essential thrombocytopenia: 2015 update on diagnosis, risk-stratification and management. *Am J Hematol* 2015;90:162-73.
9. Cassinat B, Verger E, Kiladjian JJ. Interferon Alfa Therapy in CALR-Mutated Essential Thrombocytopenia. *N Engl J Med* 2014;371:188-9.
10. Verger E, Cassinat B, Chauveau A, et al. Clinical and molecular response to interferon therapy in essential thrombocytopenia patients with CALR mutations. *Blood* 2015;126:2585-91.